

Sonography of **Elbow & Wrist**

Musculoskeletal Ultrasound Hands-on Workshop

Chueh-Hung Wu, MD, PhD

National Taiwan University Hospital
Musculoskeletal Ultrasound Center

Anatomy, surface bony **landmark**

Adequate **positioning**

Patient

Transducer

Proper **setting** of the machine

Frequency, focus, intensity, gain, etc

To get a good image

Elbow joint – effusion, arthritis

Lateral epicondyle– tennis elbow

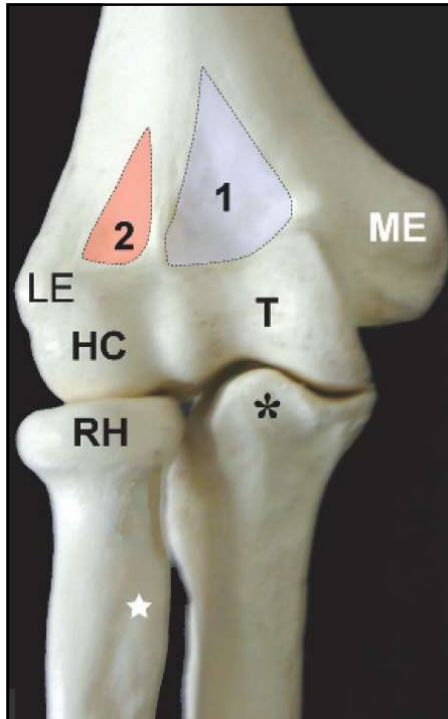
Medial UCL – pitchers

Radiocarpal / CMC joint – arthritis

APL/EPB – De Quervain disease

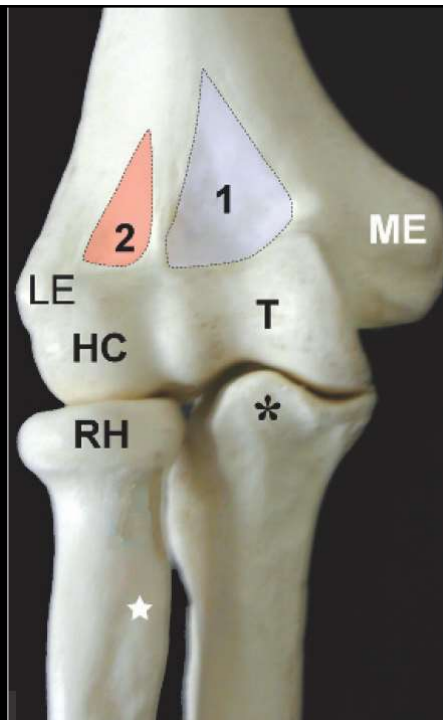
Median n. – Carpal tunnel syndrome

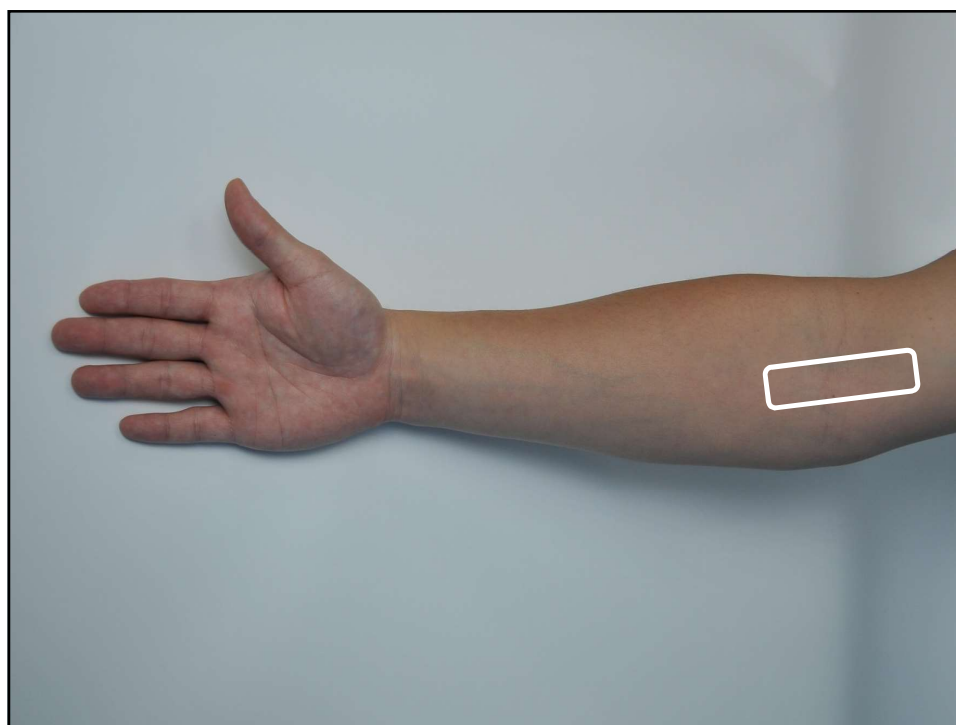
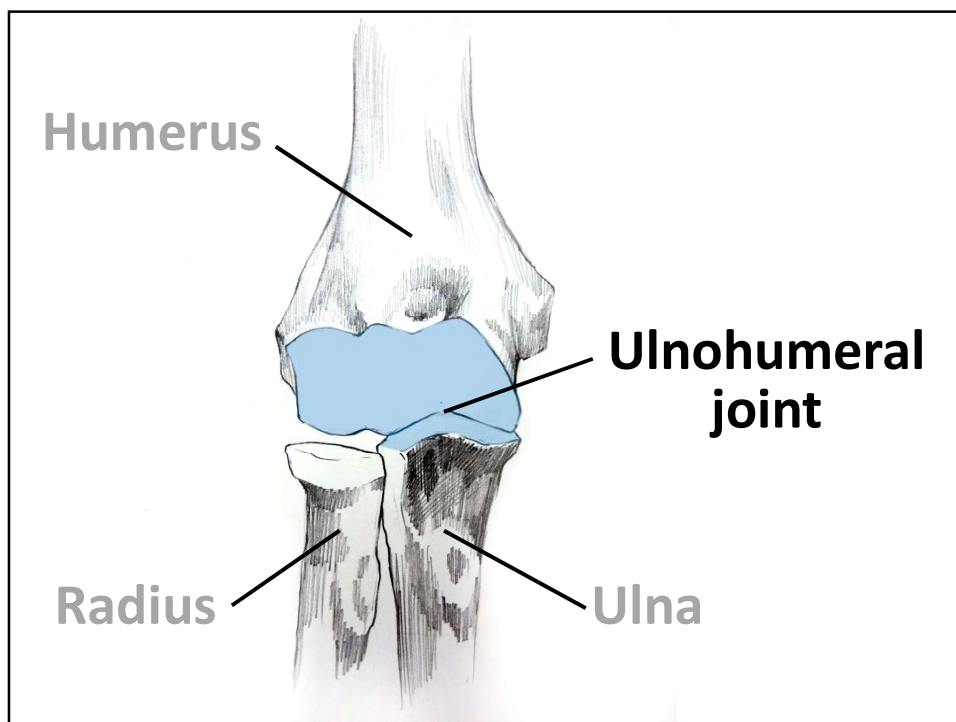
Anterior Elbow

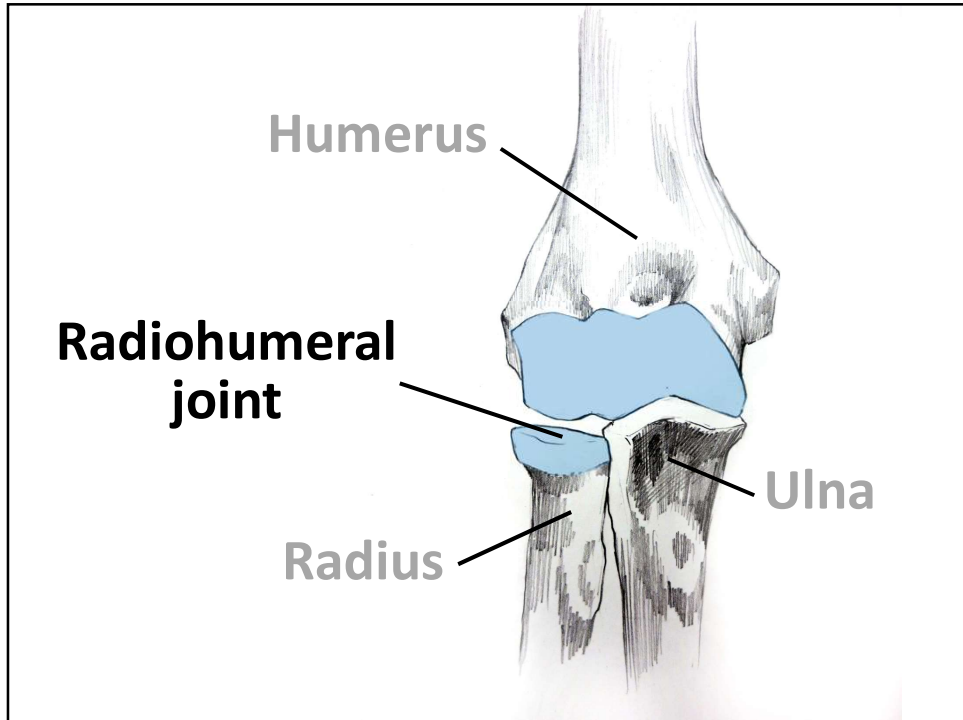
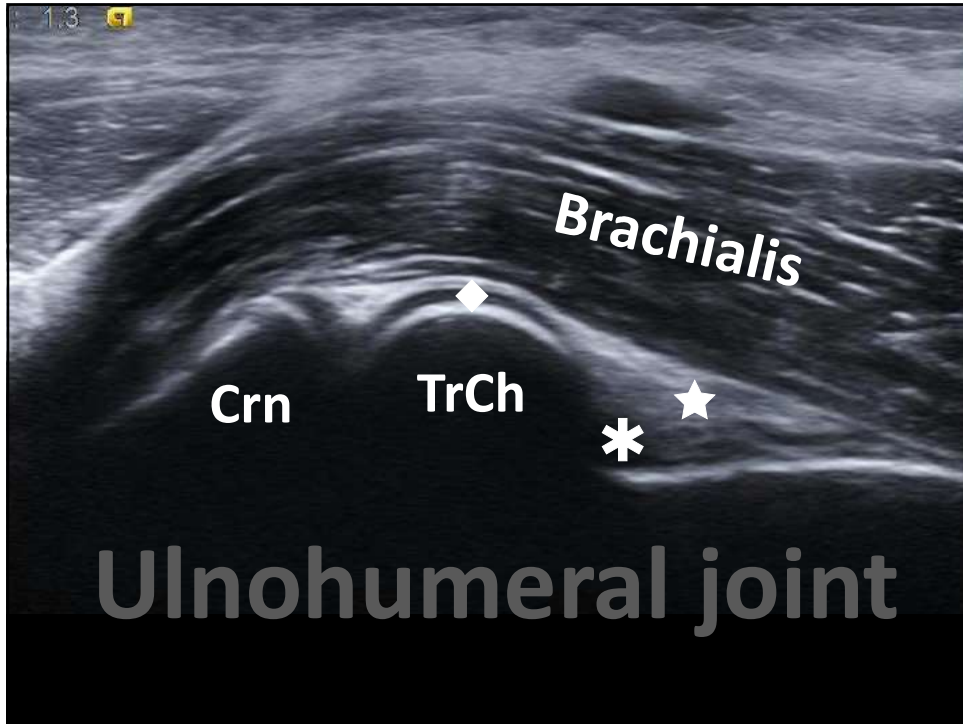


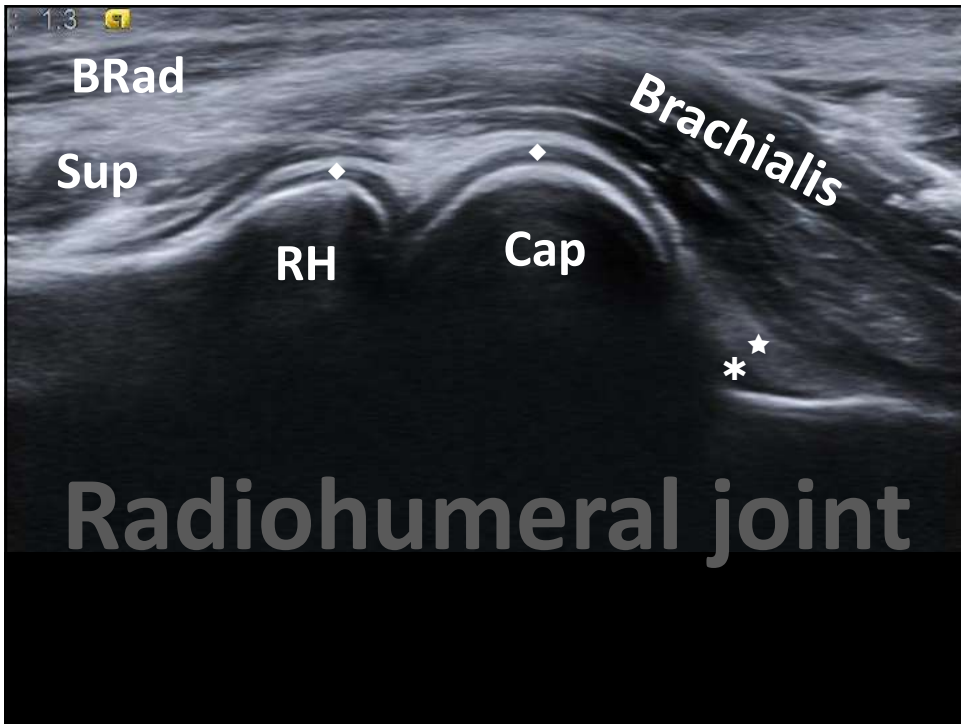
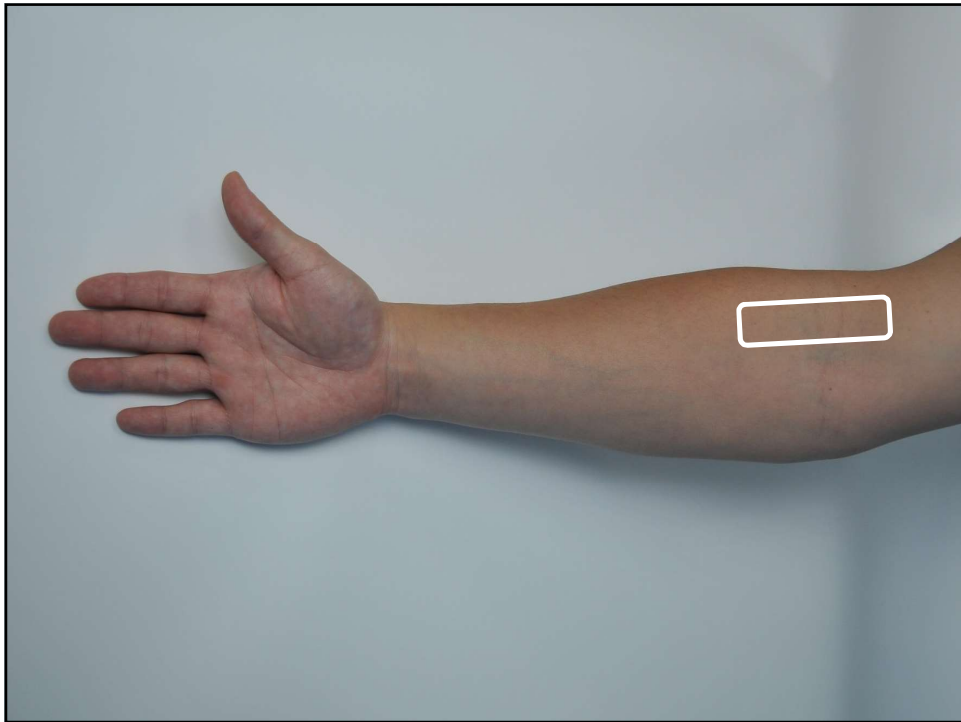
ME: medial epicondyle
1: coronoid fossa
T: Trochlea
***: coronoid process**

LE: lateral epicondyle
2: radial fossa
HC: humerus capitellum
RH: radial head

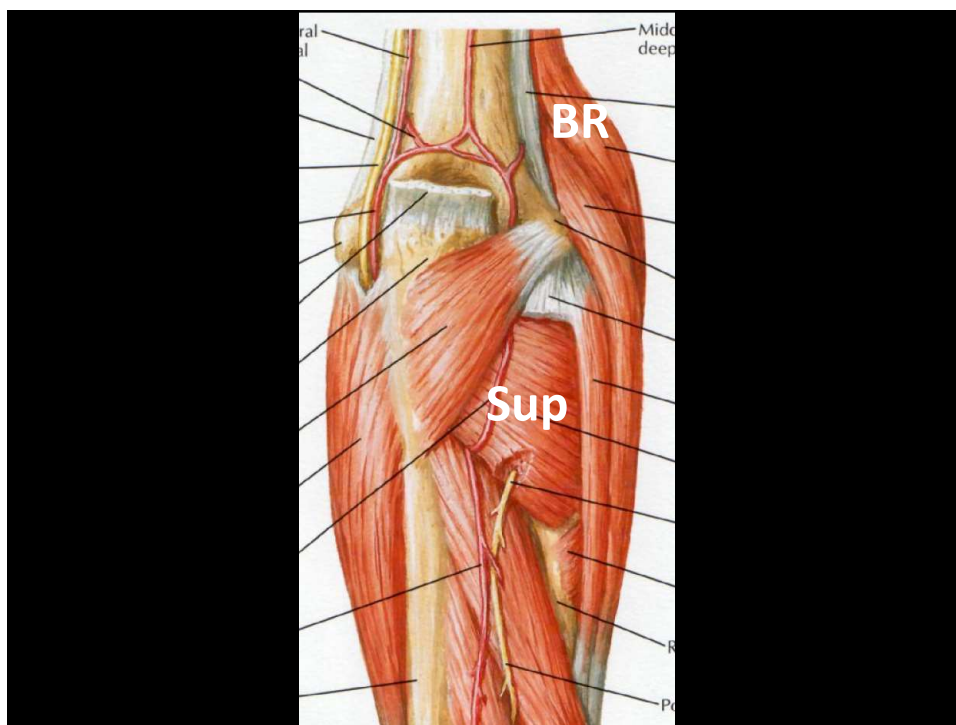


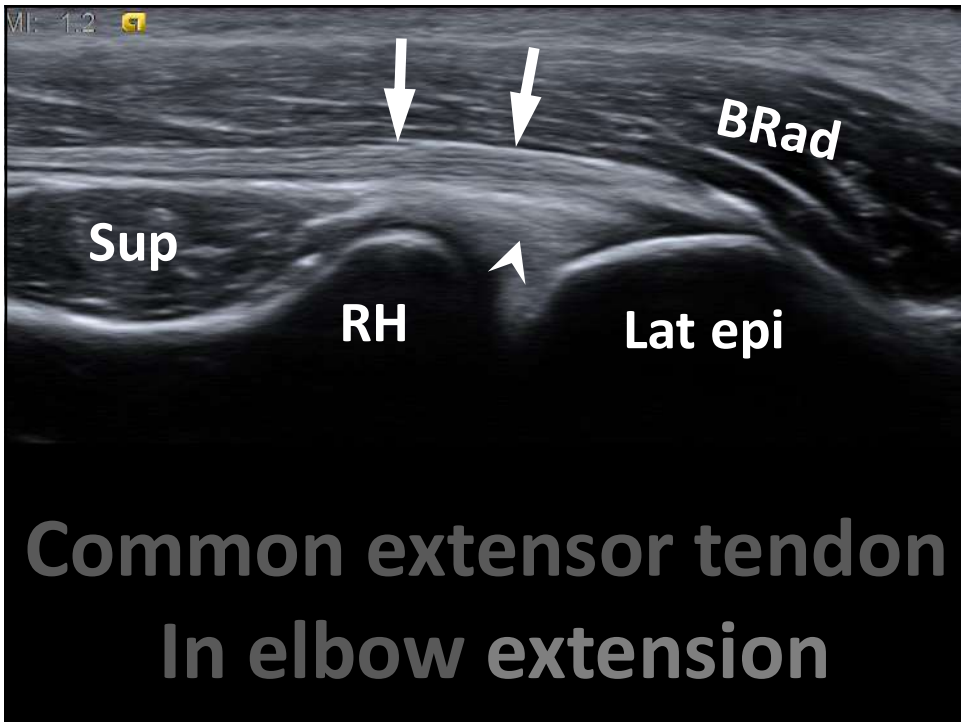
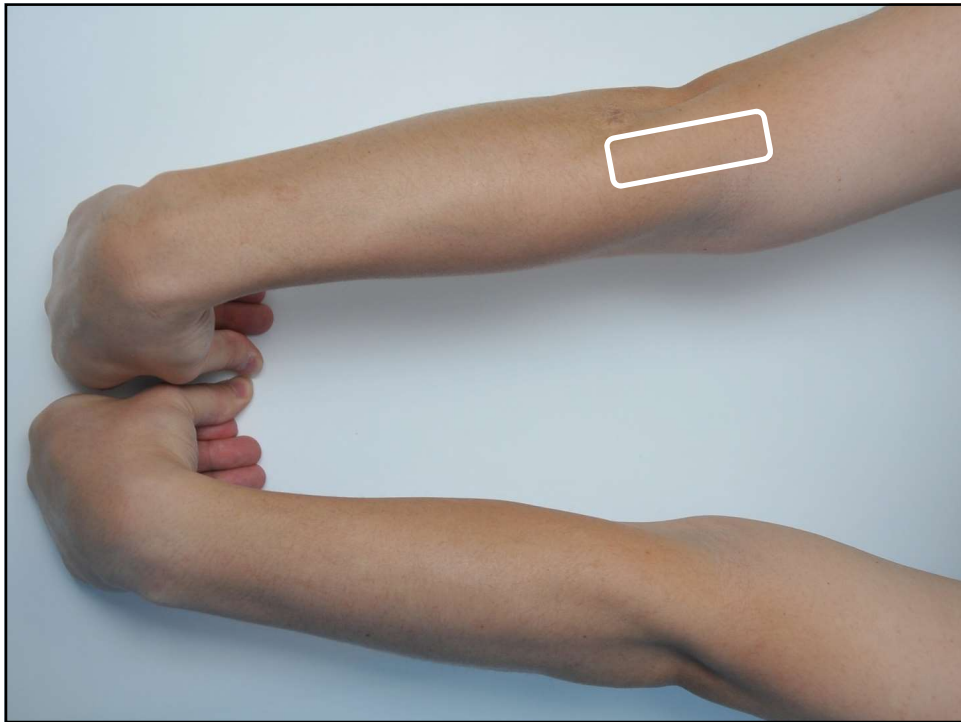


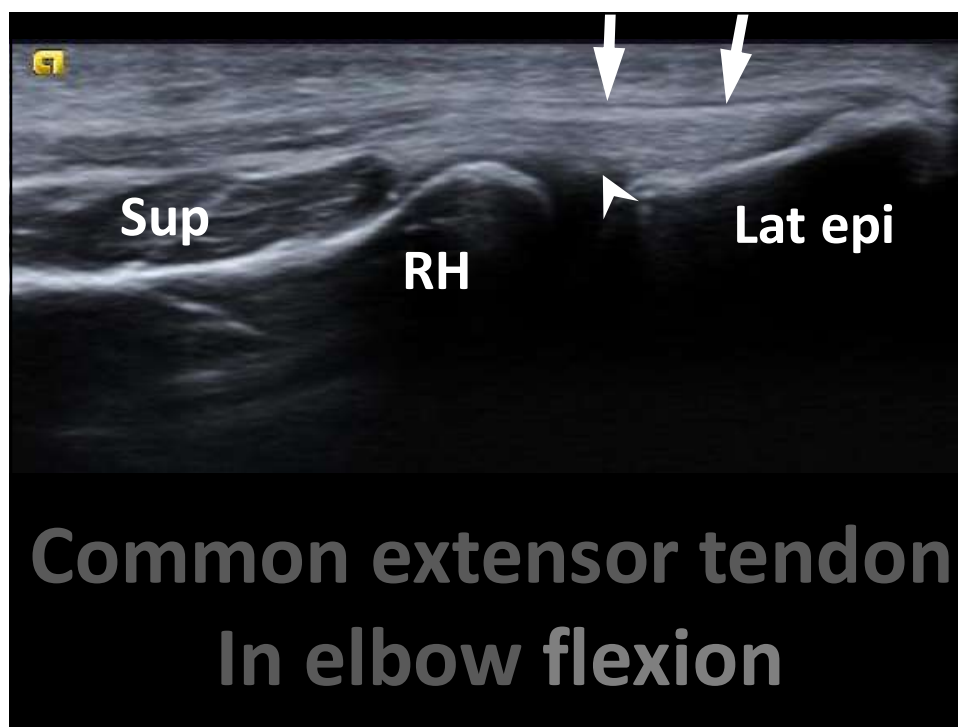
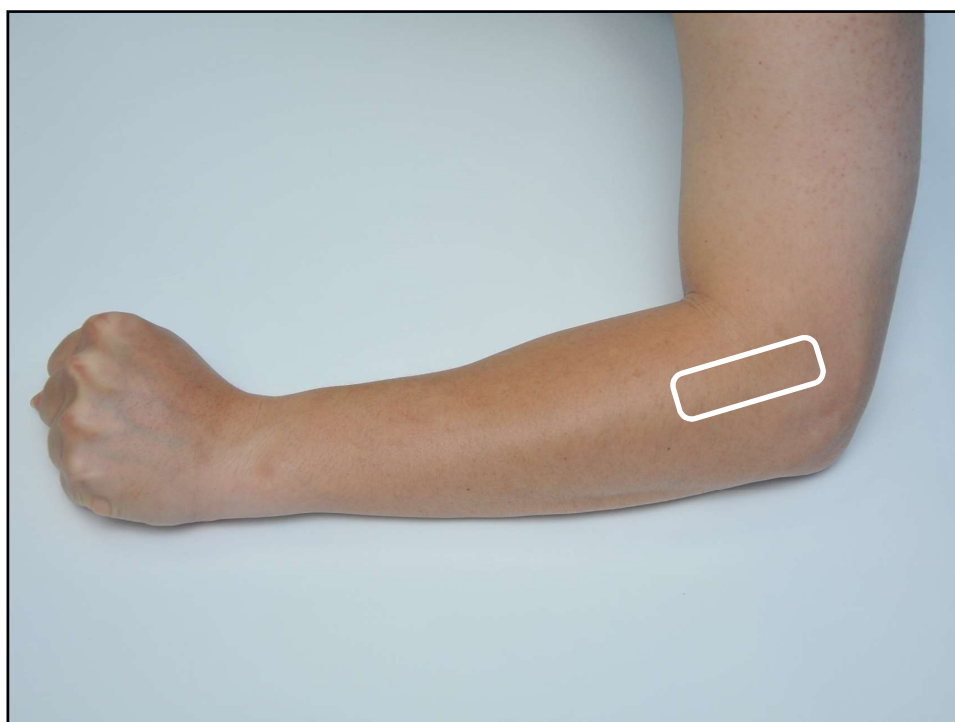


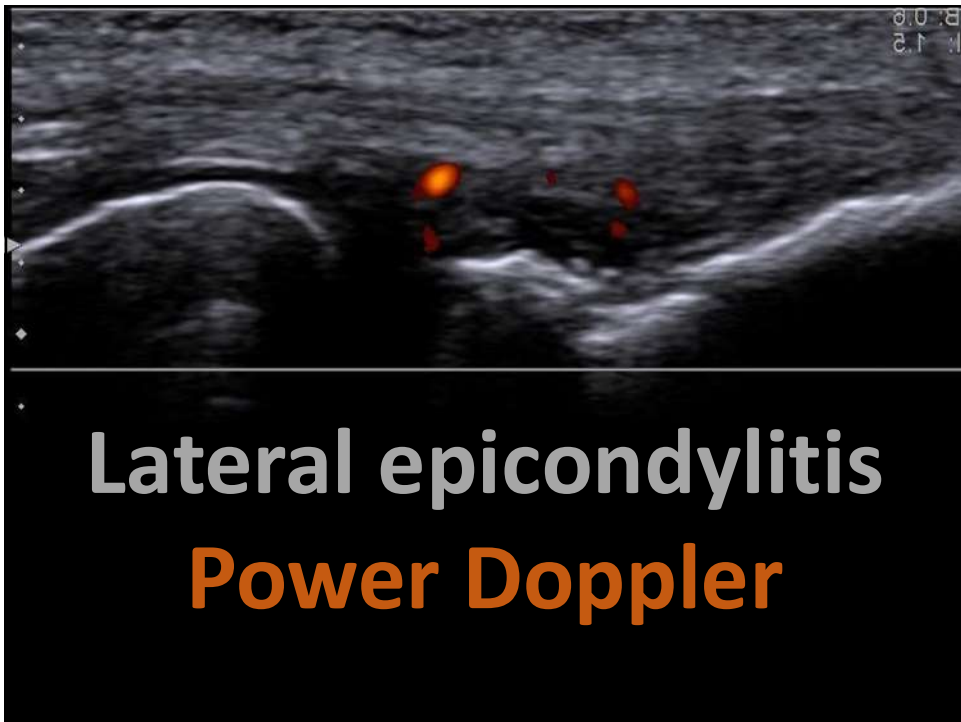
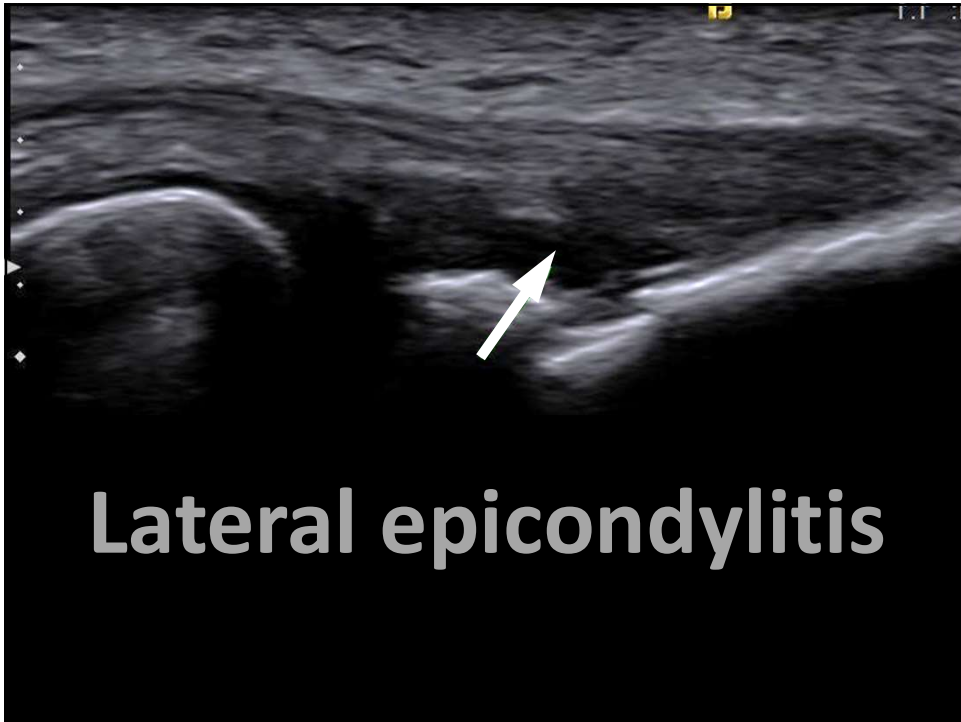

Lateral Elbow

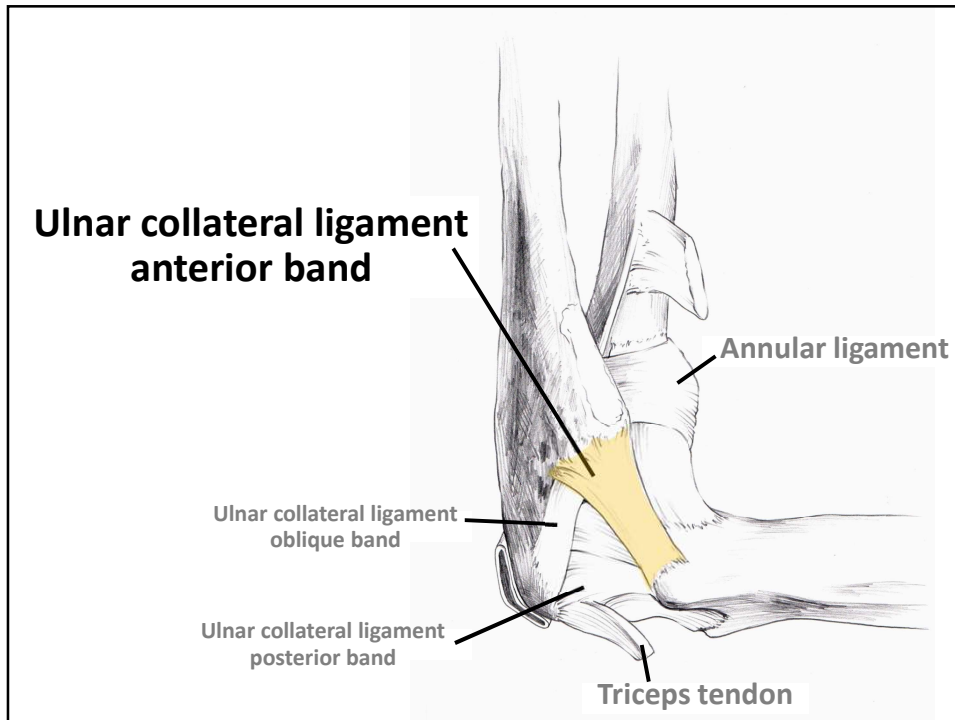


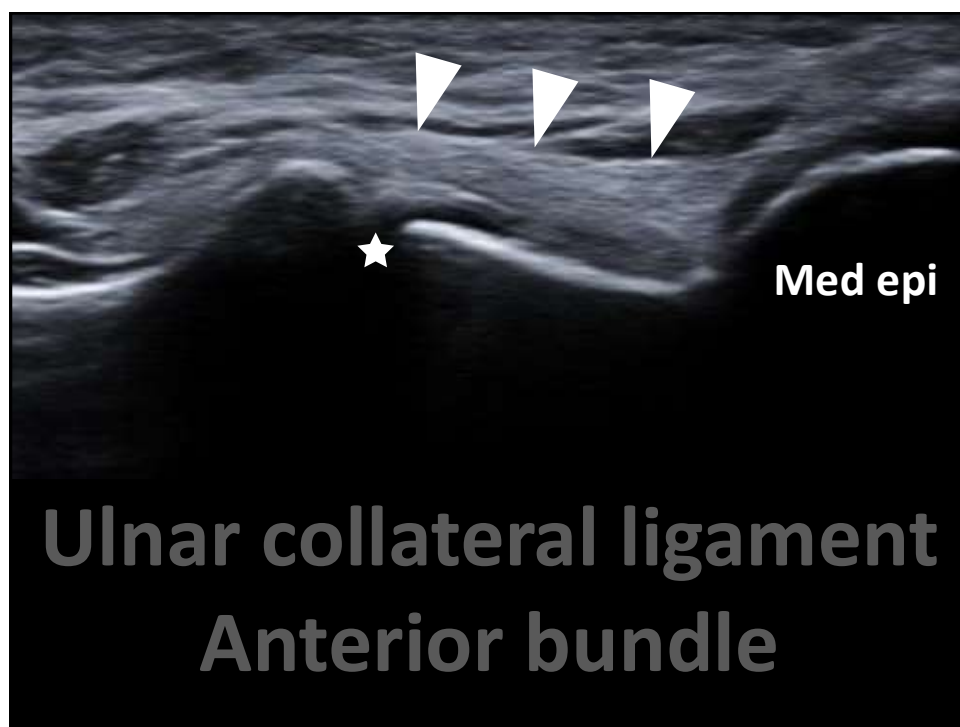
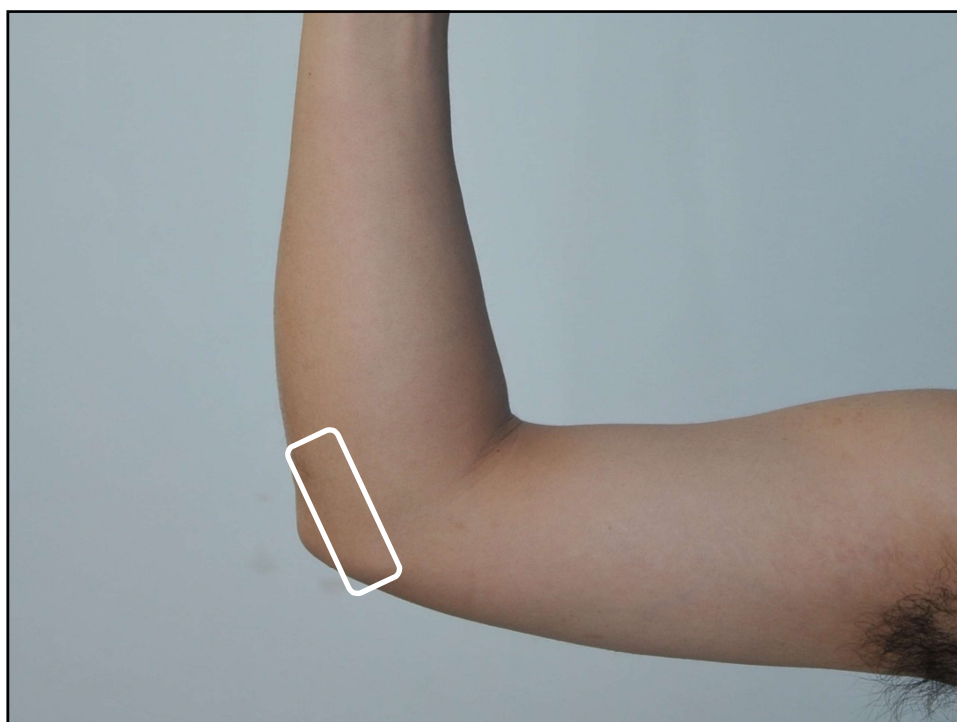


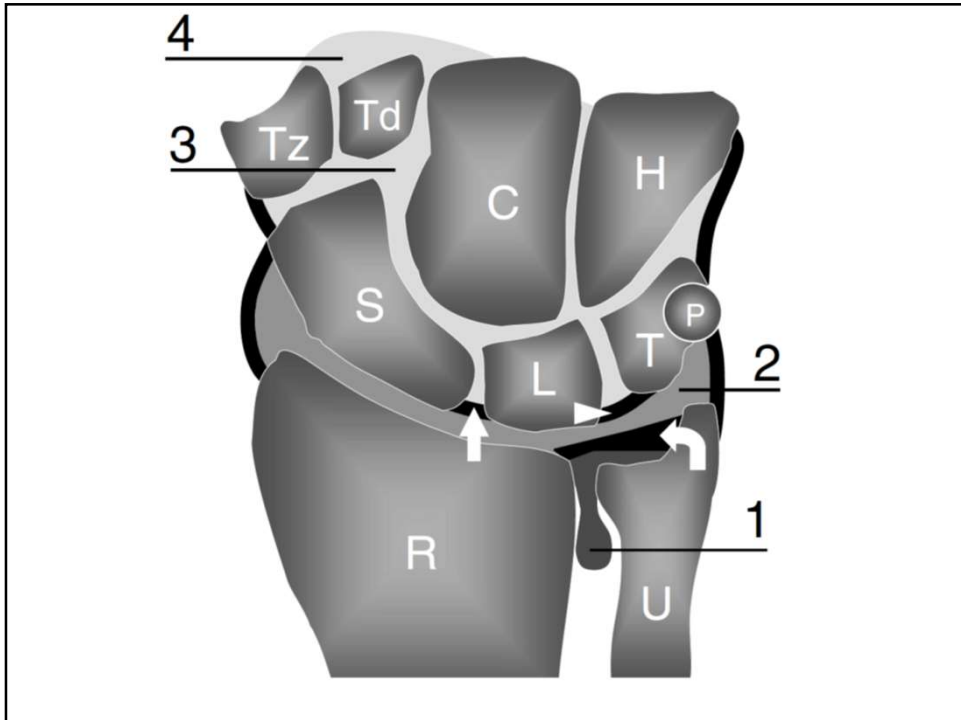
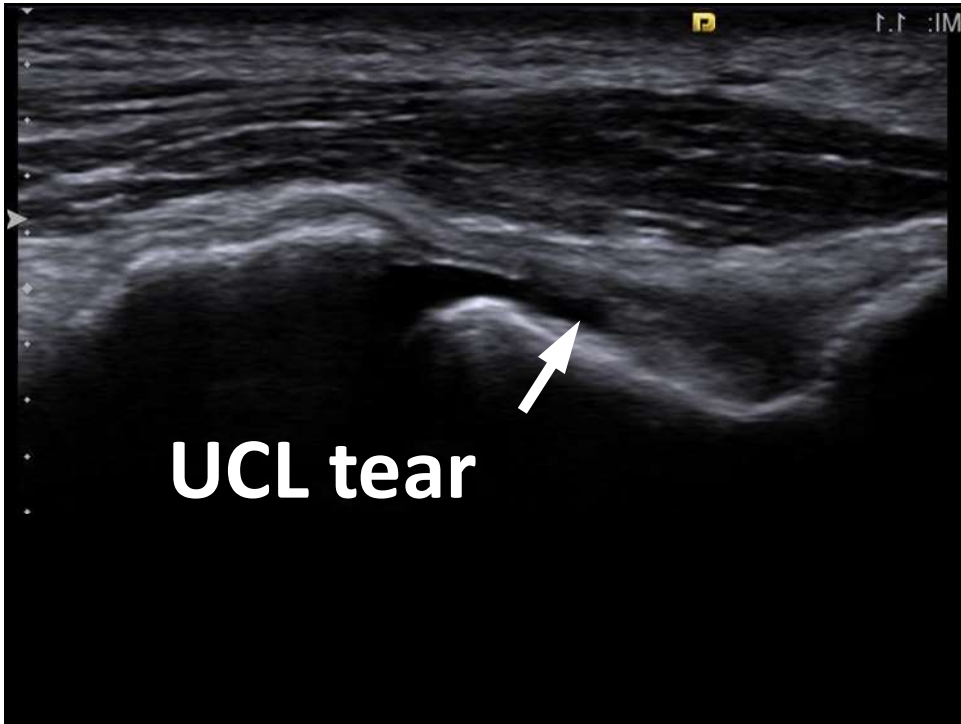


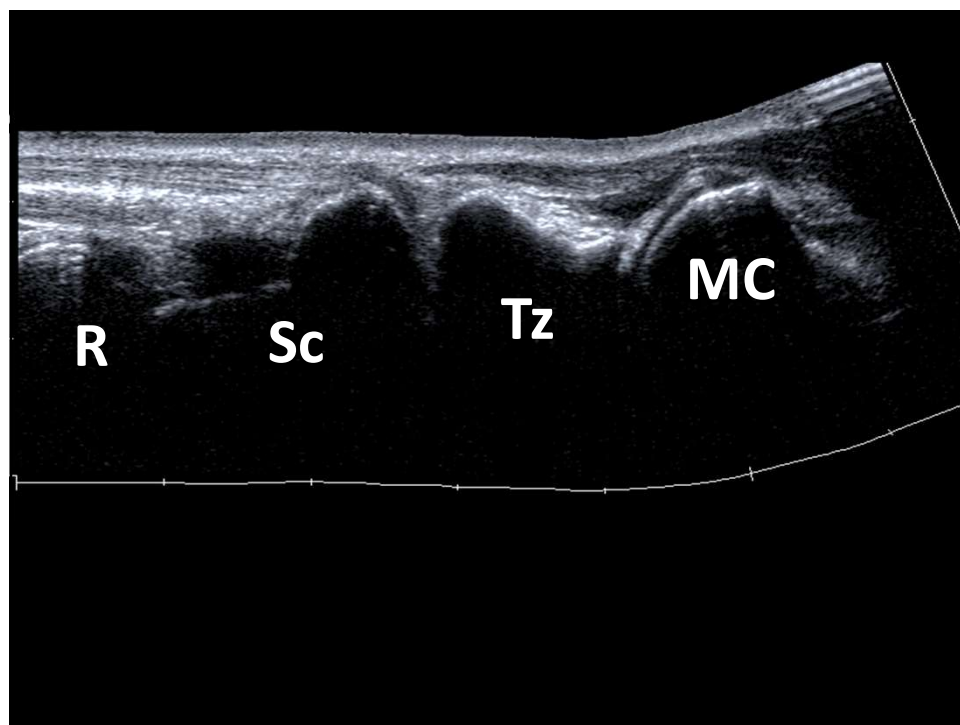
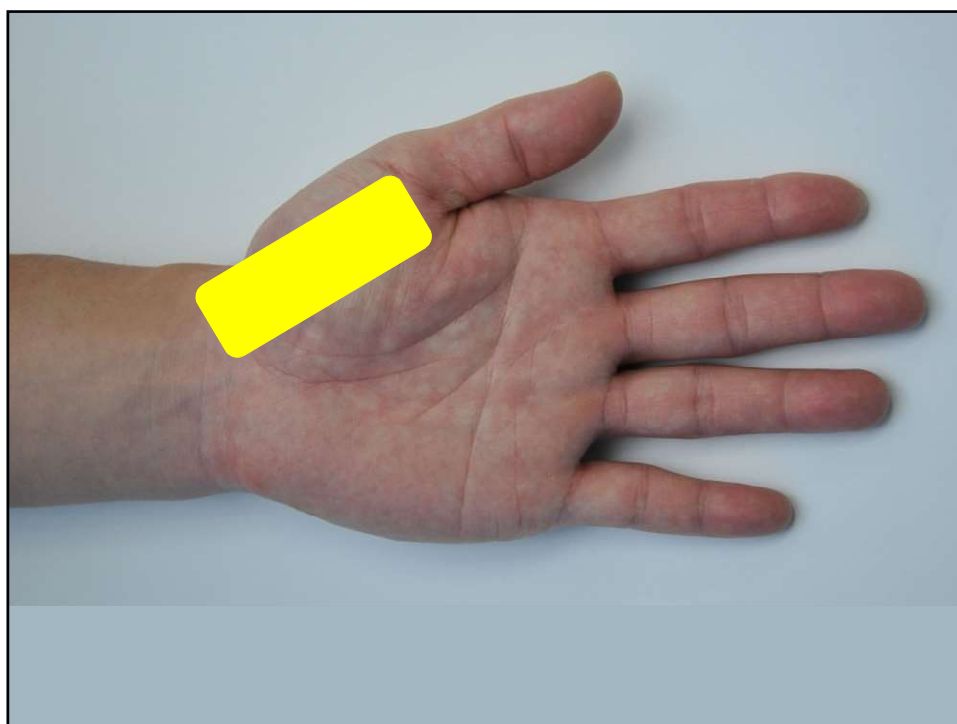


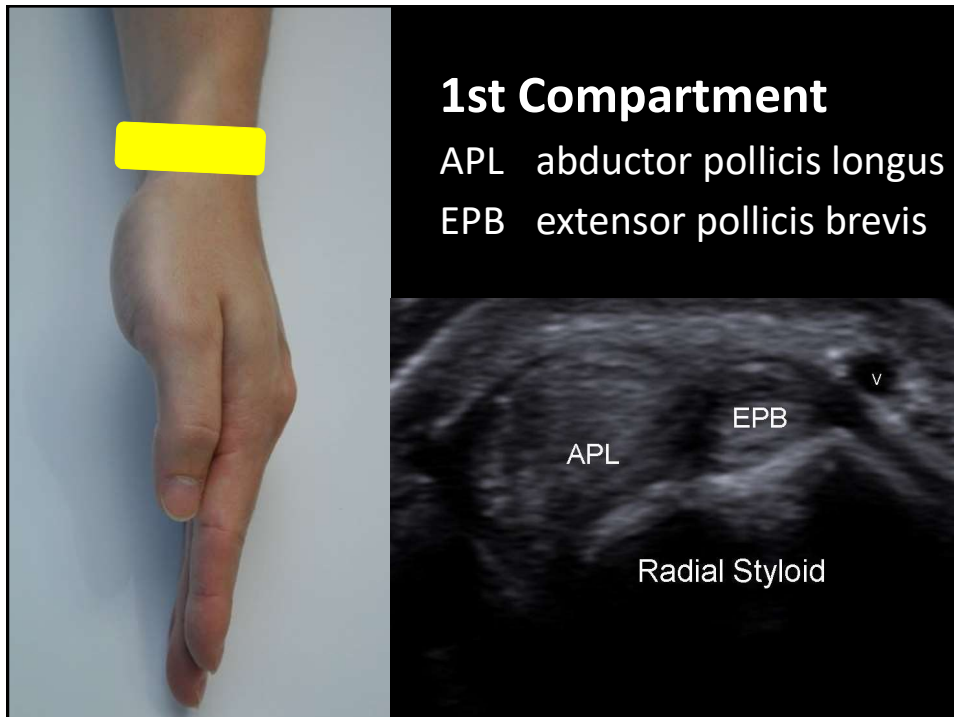
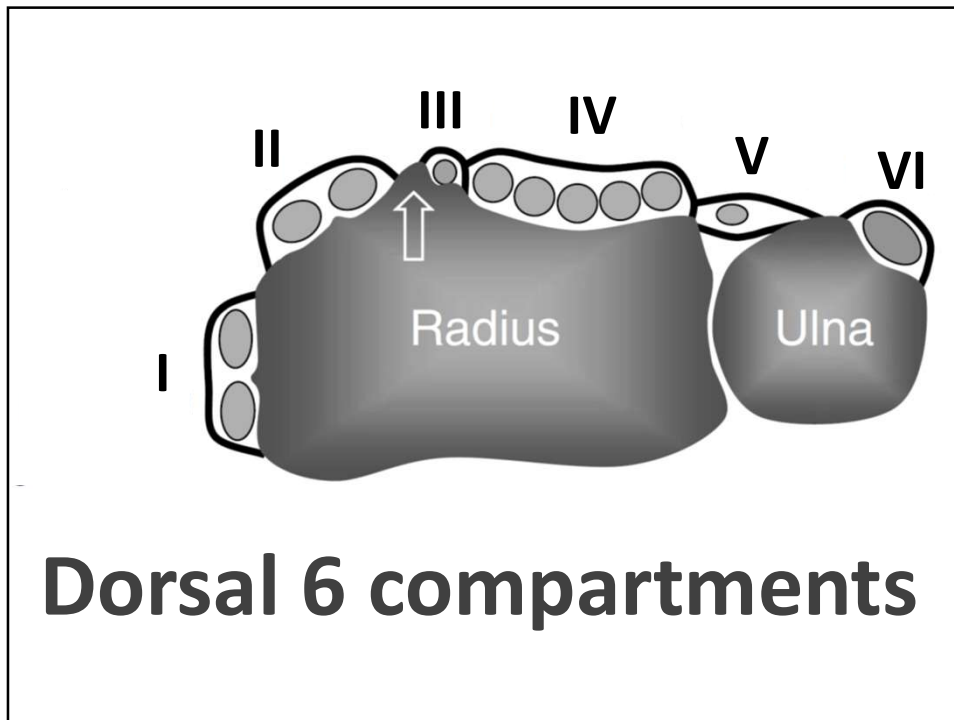
Medial Elbow

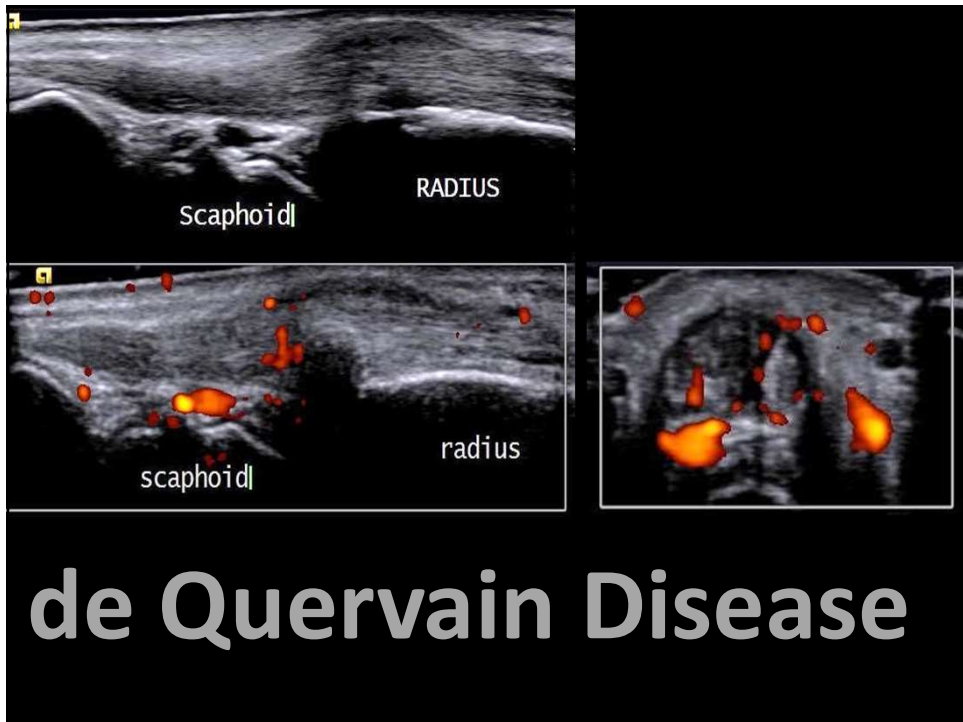
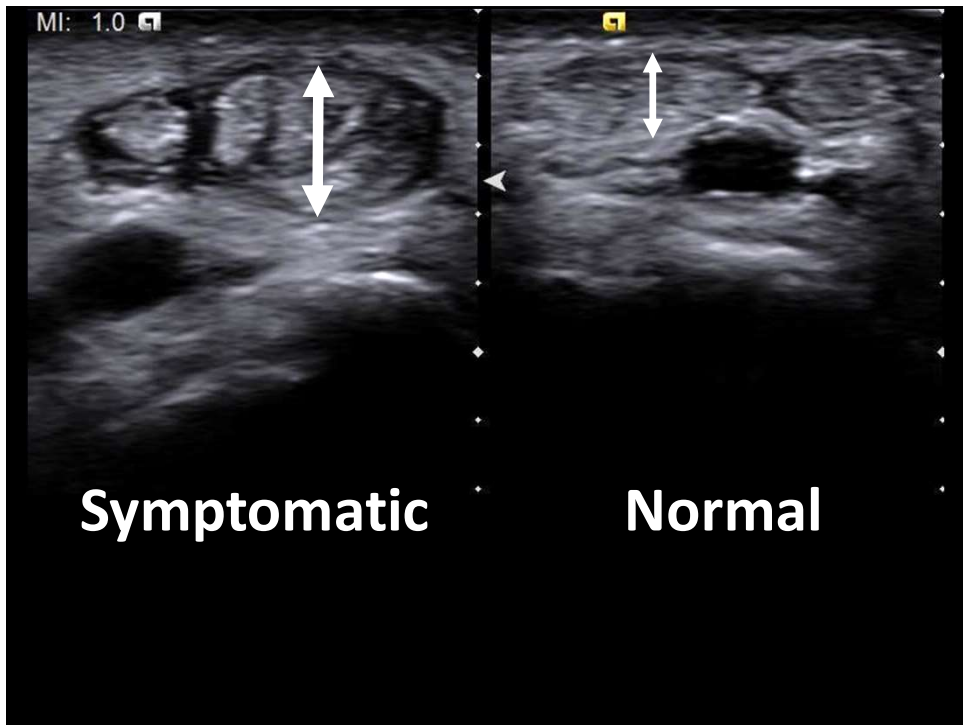


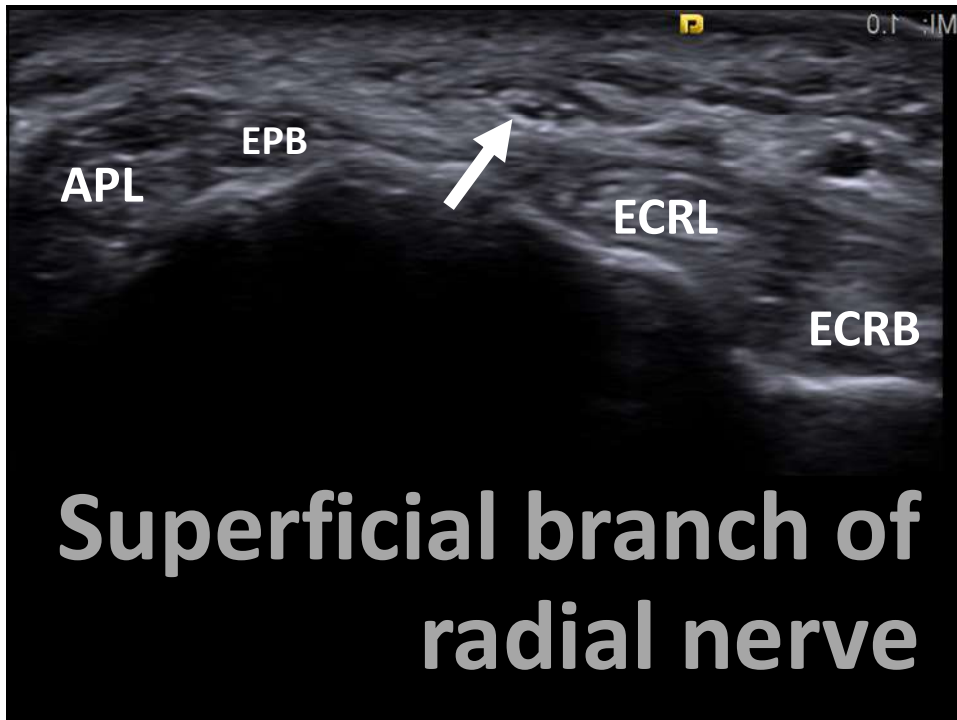
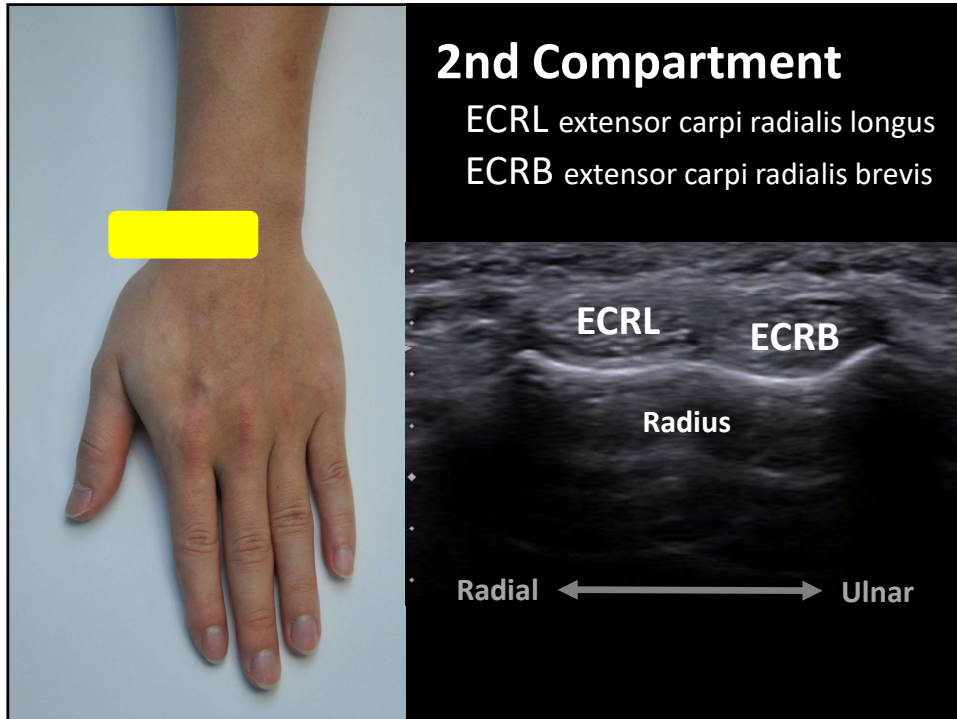


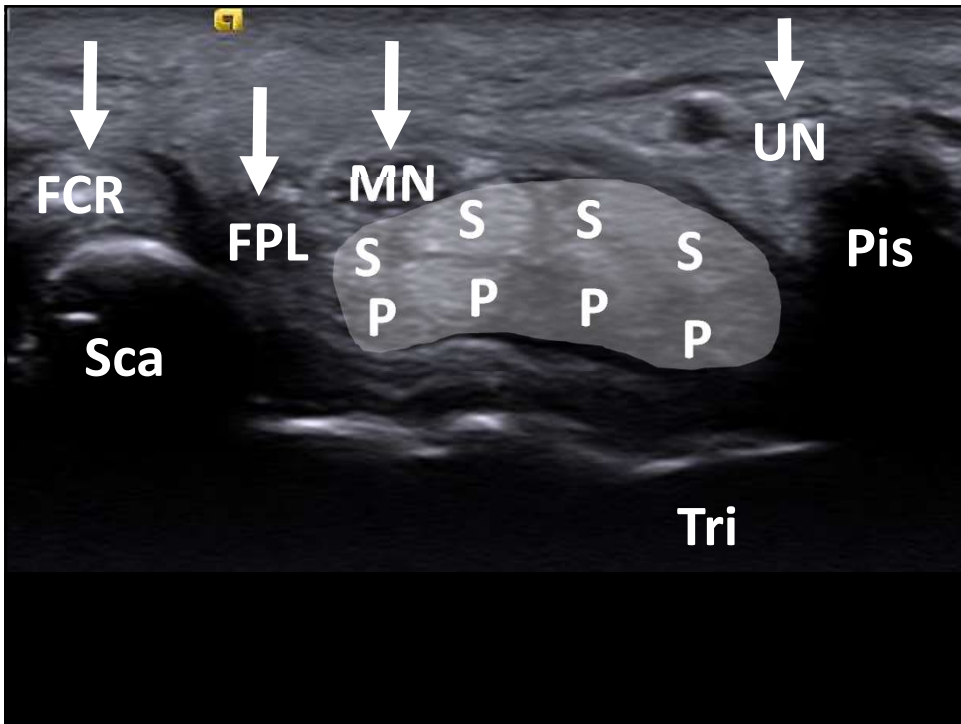
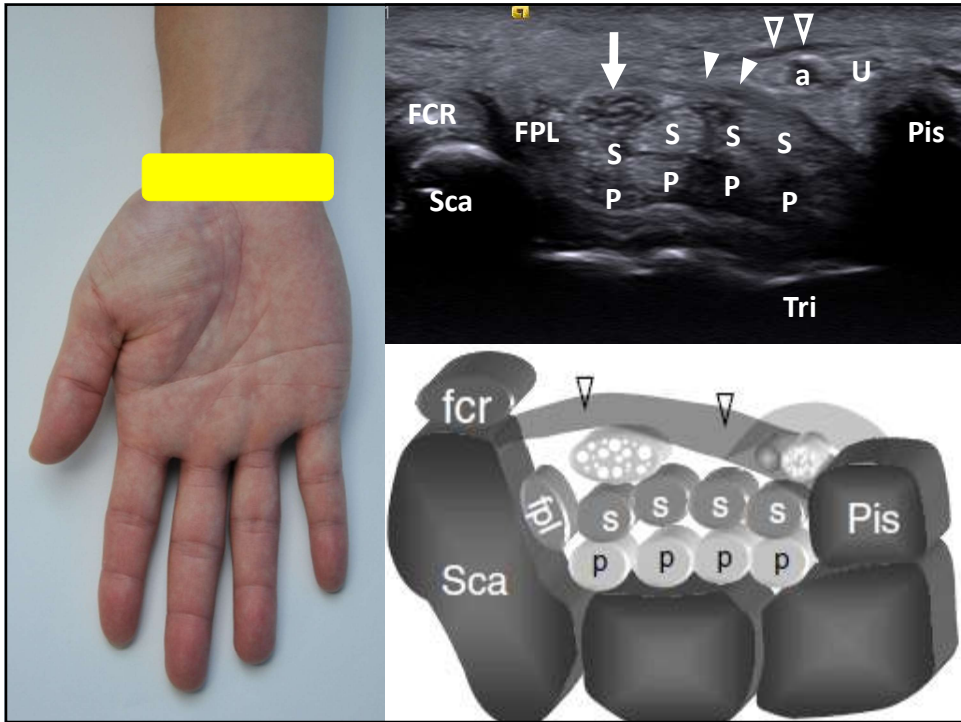


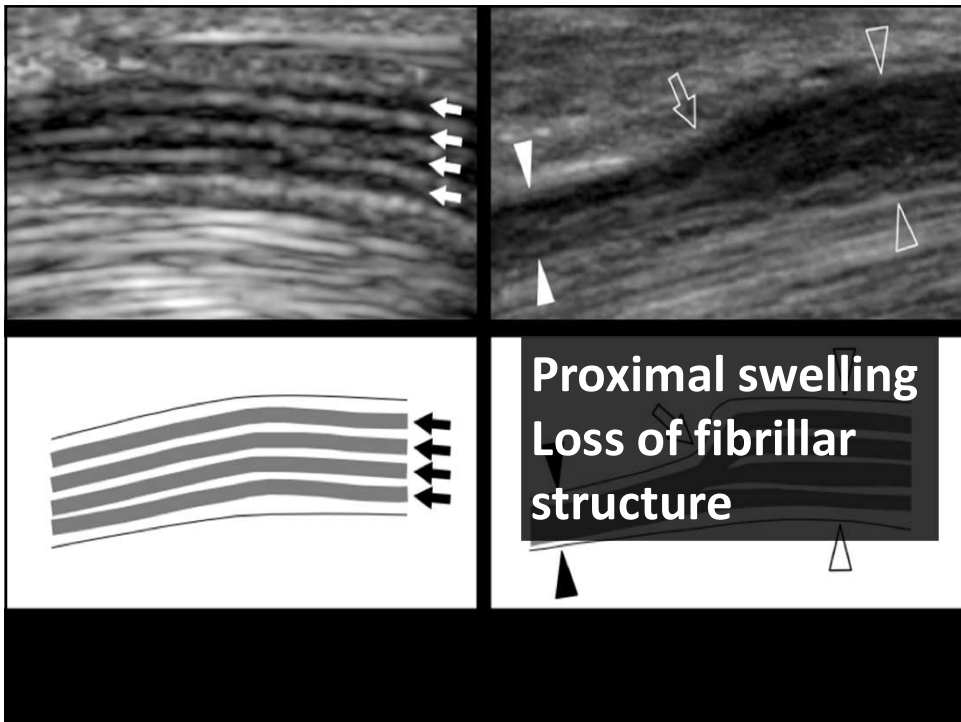
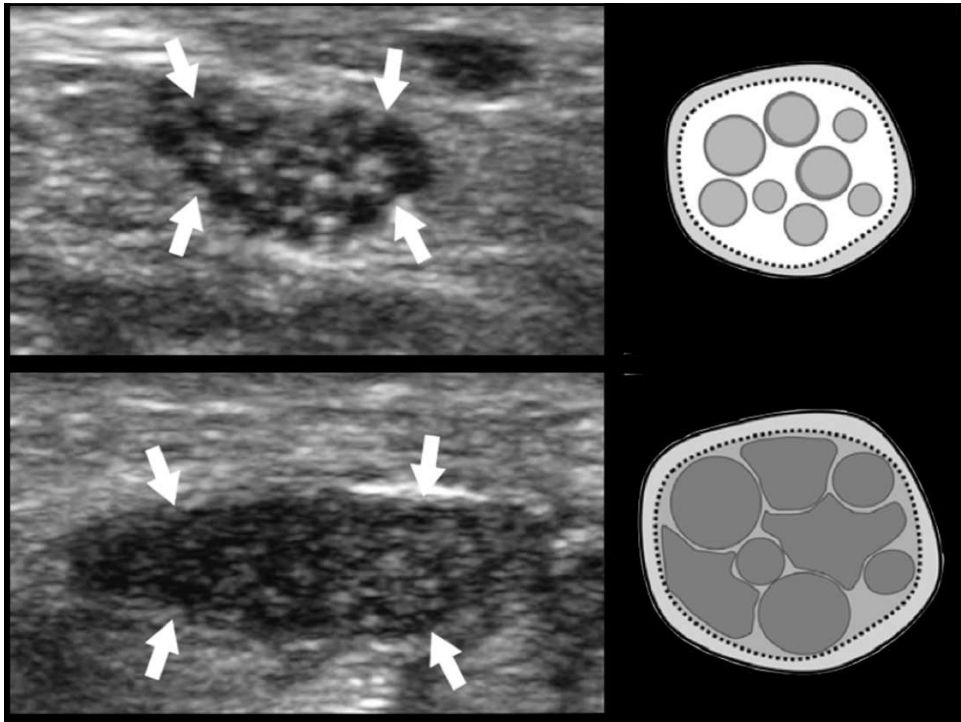


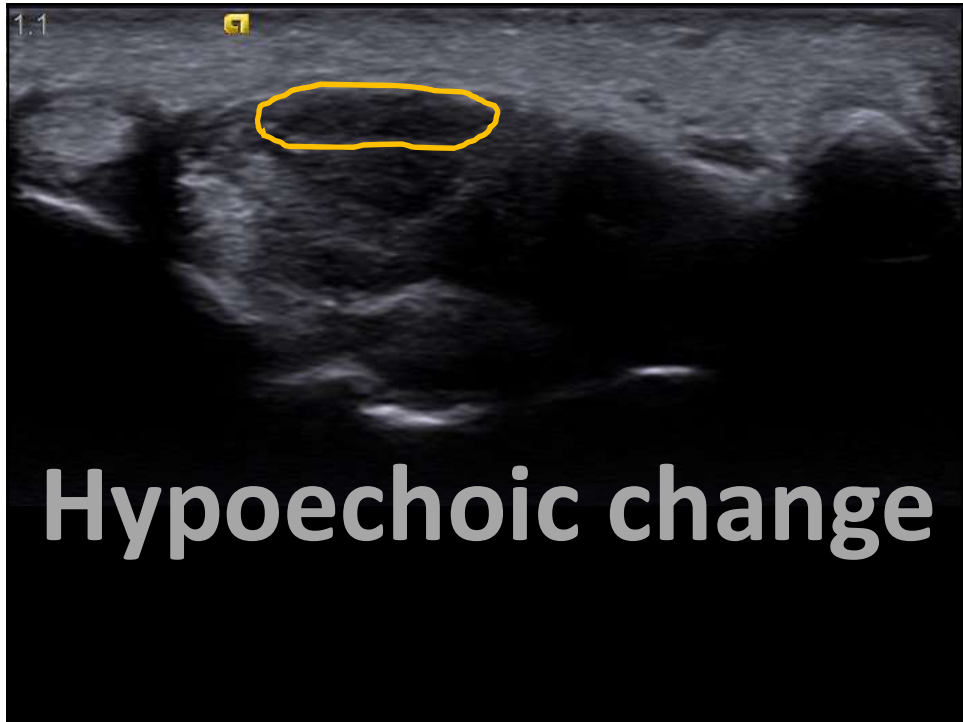
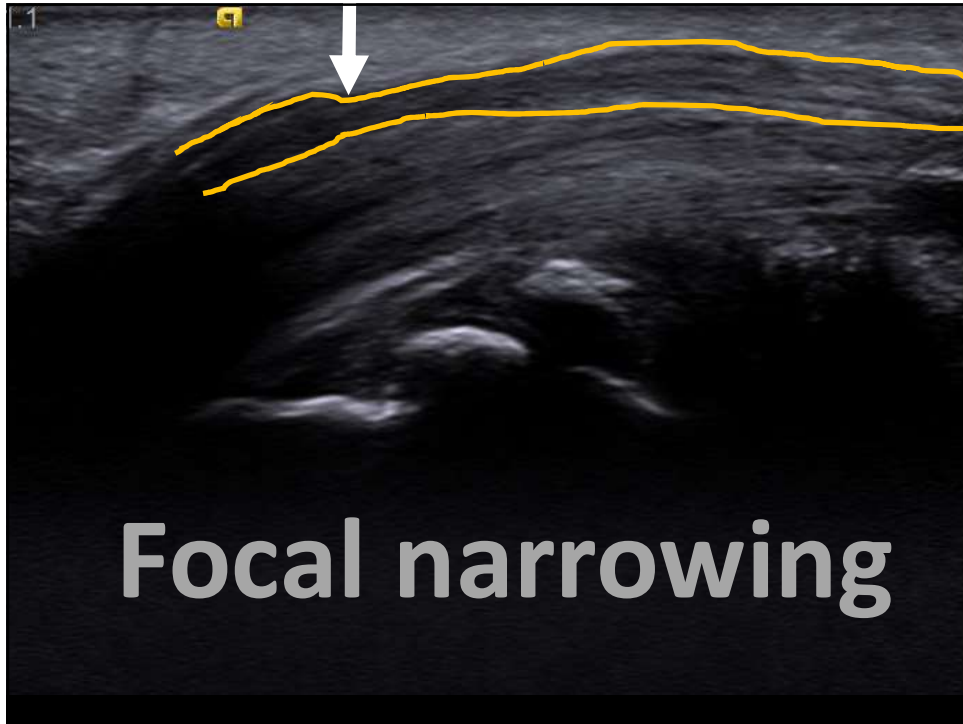


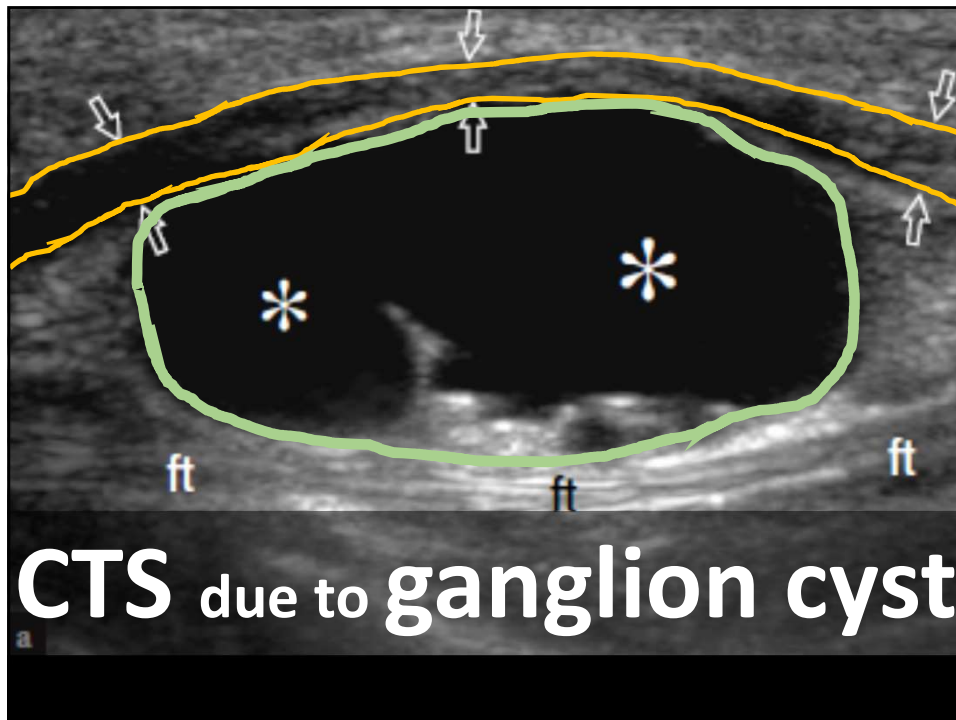












Elbow joint – effusion, arthritis

Lateral epicondyle– tennis elbow

Medial UCL – pitchers

Radiocarpal / CMC joint – arthritis

APL/EPB – De Quervain disease

Median n. – Carpal tunnel syndrome